doi: 10.13241/j.cnki.pmb.2017.27.020

聚桂醇在治疗下肢静脉曲张中初步临床应用 *

彭 娟[1] 杨 磊[1] 刘小艳[1] 占金琴[1] 朱 梅[1△] 赵凌峰[2]

（1 昆明医科大学第一附属医院超声诊断科 云南 昆明 650034；2 昆明医科大学第一附属医院血管外科 云南 昆明 650034）

摘要 目的：探讨聚桂醇在治疗下肢大隐静脉曲张中的应用价值。**方法：**回顾性分析 2013 年 9 月 -2015 年 9 月医院确诊的下肢大隐静脉曲张患者 75 例（75 条患肢）病例资料，根据治疗方案分为两组，33 例（33 条患肢）超声引导下注射聚桂醇泡沫硬化剂作为聚桂醇组，42 例（42 条患肢）行大隐静脉高位结扎 + 剥脱术作为手术组，记录手术时间、术中出血量、下床活动时间、住院时间、治疗费用及术后并发症发生率，门诊随访术后 6、12 个月，记录复发率。**结果：**聚桂醇组手术时间、下床活动时间均短于手术组，术中出血量、住院费用少于手术组，差异有统计学意义（P＜0.05）；聚桂醇组皮下血肿、皮肤麻木感发生率明显低于手术组，差异有统计学意义（P＜0.05）；聚桂醇组 12 个月复发率为 12.12 %低于手术组的 33.33 %，差异有统计学意义（P＜0.05）。**结论：**聚桂醇泡沫硬化剂注射是治疗下肢大隐静脉曲张的可选疗法。

关键词：下肢静脉曲张；聚桂醇泡沫硬化剂；超声；高位结扎；剥脱；疗效

中图分类号：R654.4 **文献标识码：**A **文章编号：**1673-6273（2017）27-5283-04

Preliminary Application of Lauromacrogol in the Treatment of Varicose Veins of Lower Limb*

PENG Juan[1], YANG Lei[1], LIU Xiao-yan[1], ZHAN Jin-qin[1], ZHU Mei[1△], ZHAO Ling-feng[2]

(1 Ultrasonic Diagnosis Department, The First Affiliated Hospital of Kunming Medical University, Yunnan, Kunming, 650034, China; 2 Department of Vascular Surgery, The First Affiliated Hospital of Kunming Medical University, Yunnan, Kunming, 650034, China)

ABSTRACT Objective: To investigate the application value of lauromacrogol in the treatment of varicose veins of lower limb. **Methods:** The medical records of 75 patients (75 affected limbs) with varicosis of great saphenous vein of lower limbs confirmed between September 2013 and September 2015 were analyzed retrospectively. According to the treatment regimen, the patients were divided into two groups. Among them, 33 cases (33 limbs) treated by ultrasound guided injection of foam sclerosing agent lauromacrogol were included in the lauromacrogol group while 42 cases (42 limbs) treated by high ligation of great saphenous vein combined with stripping were included in the operation group. The operation time, intraoperative blood loss, off-bed time, treatment costs and incidence of postoperative complications were recorded. Patients were followed up for 6 to 12 months after operation, and the recurrence rate was recorded. **Results:** The operation time, off-bed and length of hospital stay of the lauromacrogol group were shorter than those of the operation group; the intraoperative blood loss and hospitalization expenses were less than those of the operation group (P<0.05); The incidence rates of subcutaneous hematoma and skin numbness in the lauromacrogol group were significantly lower than those in the operation group (P<0.05); The 12-month recurrence rate in the lauromacrogol group (12.12%) was lower than that in the operation group (33.33%) (P<0.05). **Conclusion:** Injection of foam sclerosing agent lauromacrogol is an alternative minimally invasive therapy for treating varicosis of great saphenous vein of lower limbs.

Key words: Varicose veins of lower limb; Lauromacrogol foam sclerosing agent; Ultrasound; High ligation; Stripping; Curative effect

Chinese Library Classification(CLC): R654.4 Document code: A

Article ID: 1673-6273(2017)27-5283-04

前言

下肢大隐静脉曲张是四肢血管常见病，成年人患病率高达 27 %[1]。本病发病初期无明显症状，但随着病程的延长，可并发静脉淤积性溃疡、静脉破裂出血、血栓性脉管炎等。大隐静脉高位结扎 + 剥脱术是临床治疗大隐静脉曲张的经典术式，但术后痛苦大、复发率高[2]。近年来，超声引导下泡沫硬化剂注逐渐用于临床治疗下肢大隐静脉曲张中，可在超声引导下穿刺靶静脉，实时监测、追踪泡沫行程、弥散范围等，具有微创、疗效确切、不良反应少等优势[2]。《慢性静脉疾病硬化疗法欧洲指南》[3]指出，清洁剂类硬化剂聚桂醇注射液可通过特殊技术转变为微泡沫用于治疗下肢静脉曲张。对此，本文对比超声引导下聚桂

* 基金项目：云南省卫生科技计划项目（2014NS160）

作者简介：彭娟，硕士，主治医师，研究方向：超声靶向声学造影暨微创治疗，电话：18313789735

△ 通讯作者：朱梅，硕士，副主任医师，研究方向：超声靶向声学造影暨微创治疗，电话：18313789735

（收稿日期：2016-12-19 接受日期：2017-01-15）

醇泡沫硬化剂、隐静脉高位结扎 + 剥脱术两种方法治疗下肢大隐静脉曲张的疗效、并发症、复发率，现报道如下。

1 资料与方法

1.1 临床资料

收集我院 2013 年 9 月 -2015 年 9 月确诊并接受治疗的下肢大隐静脉曲张患者 75 例（75 条患肢）作为研究对象，经彩色超声检查显示大隐静脉为中度或重度反流，根据治疗方案分为聚桂醇组和手术组。聚桂醇组 33 例（33 条患肢），男性 12 例，女性 21 例，年龄 30～72 岁，平均（49.82± 4.16）岁；病程 2～18 年，平均（6.15± 1.28）年；国际静脉联盟分级（Clinical etiologic anatomic pathphysiologic classification，CEAP）[4]：1 例 C2 期，7 例 C3 期，15 例 C4 期，6 例 C5 期，4 例 C6 期。手术组 42 例（42 条患肢），男性 16 例，女性 26 例，年龄 32～71 岁，平均（48.63± 3.97）岁，病程 2～19 年，平均（6.43± 1.30）年；CEAP 分期：2 例 C2 期，9 例 C3 期，17 例 C4 期，8 例 C5 期，6 例 C6 期。排除 6 个月内出现心肌梗死、肺栓塞、脑卒中等疾病；硬化疗法禁忌症；排除下肢深静脉血栓形成或深静脉瓣膜严重管壁不全；双下肢大隐静脉曲张；过敏体质；合并动脉瘘；妊娠期或哺乳期妇女。两组患者性别、年龄、病程、CEAP 分期比较，差异无统计学意义（P＞0.05）。

1.2 方法

1.2.1 聚桂醇组 超声引导下聚桂醇泡沫硬化剂治疗。聚桂醇注射液 2 mL 加 8 mL 空气，液气比为 1∶4，Tessari[5]方法制成 10 mL 泡沫硬化剂备用。取站立位，彩色超声仪 ACUSON SEQUOIA512 行彩色多普勒超声检查，了解静脉走形、管壁、管腔结构、血流充盈、畸形血管的范围、与邻近组织的关系等，标记交通支静脉处及大腿中下段大隐静脉主干距体表最浅部位。取平卧位，股隐静脉连接处加压包扎。超声引导下穿刺靶血管，回抽见暗红色不凝血后缓慢注射备用的聚桂醇泡沫硬化剂，注射同时用超声探头按摩使泡沫均匀分布在注射点附近的曲张静脉；治疗期间超声实时监测，并注意观察局部皮肤颜色变化及硬化程度；每次注射泡沫硬化剂后嘱咐患者行走，预防浅静脉泡沫硬化剂经交通支进入深静脉而致深静脉血栓。每侧患肢推荐最大泡沫用量为 10 mL，由近心侧向远侧逐渐操作，单次治疗总量不宜超过 15 mL。治疗终点为患肢静脉不可压缩。术后穿医用弹力袜恢复正常活动，治疗 72 h 后去除弹力袜，以后仅在白天使用医用弹力袜，术后无需辅助用药。见如 1-2。

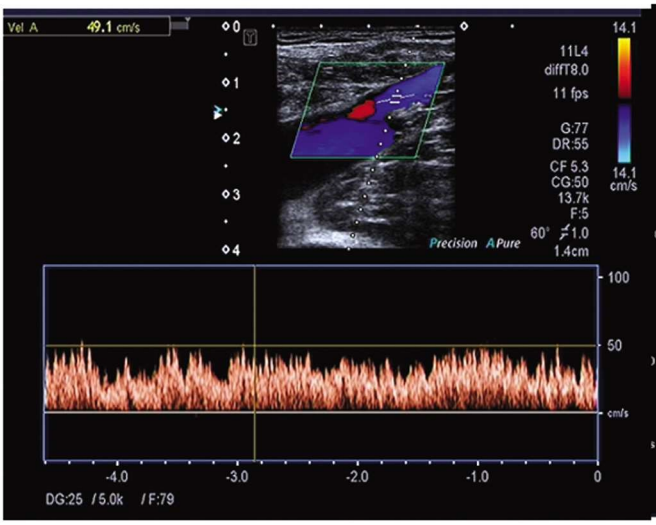

图 1 治疗前左侧大隐静脉持续性反流

Fig.1 Left great saphenous vein persistent reflux before the treatment

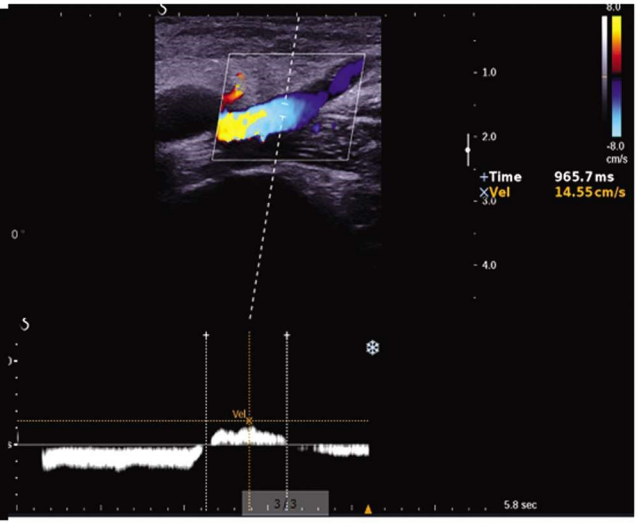

图 2 治疗后左侧大隐静脉瓣轻度反流

Fig.2 Left saphenous vein mild flux after treatment

1.2.2 手术组 行大隐静脉高位结扎 + 剥脱术治疗。硬膜外麻醉，平卧位，腹股沟卵圆窝处取一斜切口，逐层分离皮下组织，分离大隐静脉根部分支并逐一结扎，充分显露大隐静脉根部的股静脉入口，行大隐静脉主干高位结扎；分离大隐静脉远心端，向近心端剥脱膝上大隐静脉主干，常规点式结扎浅表静脉团。术后采用弹力绷带加压包扎，抬高患肢，卧床休息 6 h，嘱咐患者行床上足背屈、背伸动作；术后 6 h 下床活动，预防深静脉血栓；应用广谱抗生素预防感染，术后 3 d 去除止血绷带并穿医用弹力袜。术前合并溃疡着，定期换药，直至患肢愈合。

1.3 观察指标

① 查阅两组患者病历资料，记录两组手术时间、术中出血量、下床活动时间、治疗费用；② 术后密切观察术区皮肤、有无气促、发热、皮肤瘙痒、麻木感等，记录术后血栓性静脉炎、色素沉着、皮下硬结、皮下血肿、皮肤麻木感的发生率；③ 两组患者术后 6、12 个月在当地医院复查下肢静脉彩超，参照国际联盟分级（CEAP）了解有无出现下肢静脉曲张，采用定期电话随访记录复发率。

1.4 统计学方法

采用统计学软件 SPSS19.0 处理数据，计数资料采用%表示，采用 Fisher 确切概率法或 x^2 检验，计量资料采用 $\bar{x}\pm s$ 表示，采用 t 检验。以 P＜0.05 为差异具有统计学意义。

2 结果

2.1 两组临床观察指标比较

聚桂醇组手术时间、下床活动时间均短于手术组，术中出血量、住院费用少于手术组，差异有统计学意义（P＜0.05），见表 1。

表 1 两组临床观察指标比较

Table 1 Comparison of clinical observation indexes between the two groups

Groups	Operation time(min)	Intraoperative blood loss (mL)	Off-bed time(h)	Hospitalization expenses (yuan)
Lauromacrogol group(n=33)	32.26± 5.16	-	1.06± 0.21	4026.34± 626.17
Operation group(n=42)	80.59± 13.68	71.64± 13.50	7.16± 1.34	7516.31± 710.24
t	18.686	29.492	25.074	31.803
P	0.000	0.000	0.000	0.000

2.2 两组术后并发症发生率比较

两组血栓性静脉炎、色素沉着、皮下硬结发生率比较,差异无统计学意义(P>0.05),聚桂醇组皮下血肿、皮肤麻木感发生率明显低于手术组,差异有统计学意义(P<0.05),见表 2。

表 2 两组术后并发症发生率比较(n,%)

Table 2 Comparison of the incidence of postoperative complications between the two groups (n, %)

Groups	Subcutaneous hematoma	Thrombophlebitis	Chromatosis	Subcutaneous nodules	Subcutaneous numbness
Lauromacrogol group (n=33)	1(3.03)	1(3.03)	5(15.15)	2(6.06)	0
Operation group (n=42)	8(19.05)	2(4.76)	6(14.29)	5(11.90)	5(11.90)
x^2	4.490	2.767	0.003	0.746	4.209
P	0.034	0.096	0.959	0.388	0.040

2.3 两组 6、12 月复发率比较

聚桂醇组 12 个月复发率为 12.12%低于手术组的 33.33%,差异有统计学意义(P<0.05),两组术后 6 个月复发率比较,差异无统计学意义(P>0.05)。

表 3 两组 6、12 月复发率比较(n,%)

Table 3 Comparison of the 6-month and 12-month recurrence rate between the two groups (n, %)

Groups	6 months	12 months
Lauromacrogol group(n=33)	2(6.06)	4(12.12)
Operation group(n=42)	5(11.90)	14(33.33)
x^2	0.746	4.559
P	0.388	0.033

3 讨论

大隐静脉高位结扎+剥脱术是临床治疗下肢大隐静脉曲张的经典疗法,只要患者可耐受,均可行手术治疗。该手术方式可消除大隐静脉反流、切断大腿段深浅静脉系统的交通,且手术易于掌握,可适用于基层医院[6]。但经典手术治疗创伤大、术后恢复时间长、术后并发症和复发率高,且术后下肢皮肤遗留多个皮肤瘢痕,对美观性也有一定影响。

目前,临床治疗下肢静脉曲张的微创方法较多,如:静脉内激光、静脉内消融,但费用相对较为昂贵、需无菌手术区,在临床应用中存在局限性。硬化疗法由 Cassaigness 于 1853 年首次提出[7],以往选择性作用于轻度静脉曲张或作为手术辅助疗法;后随着微创理念、泡沫硬化剂的发展,硬化疗法逐渐用于消化道出血、血管性疾病、囊肿性疾病中,取得满意效果[8,9]。泡沫硬化剂可主要通过促使炎性闭塞达到病理性血管永久闭塞,以治疗静脉曲张、消除现有症状、改善病理学血流动力学、预防可能的并发症为主要目的;其具有独特的物理特性,静脉注射后泡沫的空泡将血管内血液推开,有利于提高血药浓度;气泡可通过影响血液流动延长滞留时间;减少硬化剂用量,降低不良用药反应发生率[10,11]。《第二届欧洲泡沫硬化剂疗法协调会议》[12]中指出,泡沫硬化剂可作用静脉曲张的微创疗法,其安全性已得到世界范围的认可。聚桂醇是属于膜活性化合物,最先作为麻醉药物引入,后经临床开发用作静脉曲张硬化剂,可在短时间内析出细胞蛋白,破坏细胞膜;有良好起泡性,不良反应少。

与传统外科手术相比,聚桂醇泡沫硬化剂注射具有以下优势:超声引导下可明确下肢各个区域静脉曲张位置,了解泡沫扩散范围;治疗期间无需麻醉,术后手术切口、明显疼痛,对日常生活无影响;治疗期间不会损伤隐神经及淋巴管;治疗创伤小,住院 3~5 d 即可出院,病情较轻患者可当日出院,缩短痊愈时间;无瘢痕组织,美观性好[13]。为提高手术效果,治疗期间还需注意一下几点:(1)治疗期间需严格掌握治疗禁忌症,包括妊娠期或长期服用避孕药物妇女;长期卧床;压迫困难的肥胖患者;严重淤积性皮炎或伴感染、结缔组织病;凝血功能异常;深静脉血栓形成或瓣膜功能不全[14];(2)重视对临床医师培训,提高其专业节能,严格把握注射位置和注射剂量,提高临床疗效,降低下肢深静脉炎、致命性肺动脉栓塞发生风险;(3)密切监测泡沫扩展范围,如在深静脉系统内发现大量泡沫,立即停止注射,嘱咐患者下床活动[15];(4)每条腿每疗程推荐剂量为 10

mL，如仍有残留可复查时继续治疗。

本研究中发现，聚桂醇组在缩短手术时间、下床活动时间上更具优势，与陆民浩等[16]研究结果一致。张艺[17]等以 120 例下肢大隐静脉曲张患者作为研究对象，聚桂醇泡沫硬化剂和传统手术的效果相当，但聚桂醇泡沫硬化剂治疗的患者手术时间、下床活动时间相对较短。聚桂醇用药安全性也是临床观察重点，多项文献报道，聚桂醇泡沫硬化剂的不良反应少可接受的，多以轻度不良事件为主[18]。本研究中，聚桂醇组患者的皮下血肿、皮肤麻木感发生率相对较低。有学者认为，皮肤麻木感由术中剥抽浅表病变静脉时损伤部分微小皮肤神经引起[19]。另外，研究发现聚桂醇泡沫硬化剂治疗下肢大隐静脉损伤可降低术后复发率。焦亚彬等[20]对比聚桂醇泡沫硬化剂注射治疗与腔内电凝治疗下肢静脉曲张的效果，发现两种治疗方案疗效相当，但聚桂醇泡沫硬化剂注射治疗后 1 年复发率相对较低。

综上所述，聚桂醇泡沫硬化剂静脉注射治疗下肢大隐静脉损伤效果确切，可缩短手术时间、住院时间，减少治疗费用，降低术后并发症发生率和复发率。

参 考 文 献(References)

[1] Flore R, Ponziani F R, Gerardino L, et al. Biomarkers of low-grade inflammation in primary varicose veins of the lower limbs[J]. European Review for Medical & Pharmacological Sciences, 2015, 19 (4): 557-562

[2] 王晓. 大隐静脉高位结扎联合剥脱术治疗原发性大隐静脉曲张的疗效观察[J]. 中国医药导刊, 2014, 16(3): 410-411
Wang Xiao. Curative Effect Observation on Great Saphenous Vein High Ligation Joint Peeling Treatment of Primary Great Saphenous Varicose Veins [J]. Chinese Journal of Medical Guide, 2014, 16(3): 410-411

[3] 李龙.《慢性静脉疾病硬化疗法欧洲指南》解读[J]. 介入放射学杂志, 2016, (9): 743-749
Li Long. Explanation of " European Guidelines for Sclerotherapy in Chronic Venous Disorders" [J]. Journal of Interventional Radiology, 2016, 25(9): 743-749

[4] Rabe E, Pannier F. Clinical, aetiological, anatomical and pathological classification (CEAP): gold standard and limits[J]. Phlebology, 2012, 27 Suppl 1(27 Suppl 1): 114-118

[5] Alessandro Frullini MD FACP, Attilio Cavezzi M D. Sclerosing Foam in the Treatment of Varicose Veins and Telangiectases: History and Analysis of Safety and Complications [J]. Dermatologic Surgery, 2002, 28(1): 11-15

[6] 段友良, 徐良. 大隐静脉高位结扎剥脱术治疗静脉曲张并下肢深静脉瓣膜功能不全 32 例效果观察[J]. 山东医药, 2012, 52(35): 71-72
Duan You-liang, Xu Liang. Observation on the effect of high ligation of great saphenous vein and stripping in the treatment of varicose veins with lower extremity deep vein valve insufficiency in 32 cases [J]. Shandong Medical Journal, 2012, 52(35): 71-72

[7] 邱天, 崔明, 严枫, 等. 泡沫硬化疗法 - 我们的新选择 [J]. 西南国防医药,2012 ,22(12): 1426-1428
Qiu Tian, Cui Ming, Yan Feng, et al. Foam sclerotherapy - our new choice [J]. Medical Journal of National Defending Forces in Southwest China, 2012, 22(12): 1426-1428

[8] 覃忠, 覃晓, 郭思恩, 等. 泡沫硬化剂联合手术治疗在下肢静脉曲张中的应用[J]. 广西医科大学学报, 2015, 32(6): 944-946
Qin Zhong, Qin Xiao, Guo Si-en, et al. Application of foam sclerosing agent combined with operation in the treatment of varicose veins of lower extremity [J]. Journal of Guangxi Medical University, 2015, 32 (6): 944-946

[9] 范金强, 李振军, 江剑华, 等. 硬化疗法治疗临床难治性瘘的应用现状[J]. 医学综述, 2015, 21(3): 459-460, 461
Fan Jin-qiang, Li Zhen-jun, Jiang Jian-hua, et al. The Application Status of Sclerotherapy Treat in Refractory Fistula[J]. Medical Recapitulate, 2015, 21(3): 459-460, 461

[10] 董利英. 腔内激光联合泡沫硬化剂治疗下肢静脉曲张的护理体会[J]. 护士进修杂志, 2013, 28(20): 1880-1881
Dong Li-ying. Nursing of the treatment of varicose veins of lower extremity treated with endovenous laser ablation combined with foam sclerosing agent [J]. Journal of Nurses Training, 2013, 28 (20): 1880-1881

[11] 贾琪, 吴丹明, 王成刚 等. 彩超引导下聚桂醇泡沫硬化剂注射治疗下肢静脉曲张[J]. 中国微创外科杂志, 2016, 16(3): 276-278
Jia Qi, Wu Dan-ming, Wang Cheng-gang, et al. Color Ultrasound Guided Lauromacrogol Foam Sclerotherapy for Varicose Vein [J]. Chinese Journal of Minimally Invasive Surgery, 2016, 16(3): 276-278

[12] Breu F X, Guggenbichler S, Wollmann J C. 2nd European Consensus Meeting on Foam Sclerotherapy, 28-30 April 2006, Tegernsee, Germany [J]. Vasa. Zeitschrift Fuür Gefaässkrankheiten. journal for Vascular Diseases, 2008, 37 Suppl 71(Suppl 71): 1-29

[13] 闫如虎, 吕维富, 张万高, 等. DSA 引导下使用聚桂醇泡沫硬化剂治疗下肢静脉曲张[J]. 实用放射学杂志, 2014, 30(10): 1719-1722, 1726
Yan Ru-hu, Lv Wei-fu, Zhang Wan-gao, et al. DSA-guided foam sclerotherapy of lauromacrogol in treatment of lower extremity varicose veins [J]. Journal of Practical Radiology, 2014, 30 (10): 1719-1722, 1726

[14] 朱永强, 徐敬宣, 陈俊英, 等. 透视引导下聚桂醇泡沫硬化剂治疗下肢静脉曲张的疗效观察 [J]. 中华放射学杂志, 2012, 46(9): 836-839
Zhu Yong-qiang, Xu Jing-xuan, Chen Jun-ying, et al. The clinical efficacy observation of fluoroscopy-guided foam sclerotherapy with lauromacrogol for varicose veins of the lower extremities[J]. Chinese Journal of Radiology, 2012, 46(9): 836-839

[15] 包国宏, 王华珍, 龚小玲, 等. 大、小隐静脉结扎联合聚桂醇泡沫硬化剂治疗下肢静脉曲张 [J]. 中华整形外科杂志, 2015, 31(3): 230-231
Bao Guo-hong, Wang Hua-zhen, Gong Xiao-ling, et al. Treatment of varicose veins of lower extremity with ligation of large and small saphenous veins combined with lauromacrogol foam sclerosing agent [J]. Chinese Journal of Plastic Surgery, 2015, 31(3): 230-231

[16] 陆民浩, 杨静, 赵滨, 等. 泡沫硬化剂联合大隐静脉高位结扎术治疗下肢静脉曲张的研究 [J]. 临床和实验医学杂志, 2015, 14(2): 149-151
Lu Min-hao, Yang Jing, Zhao Bin, et al. Foam hardener therapy combined saphenous vein ligation treatment for varicose veins[J]. Journal of Clinical and Experimental Medicine, 2015, 14(2): 149-151

（下转第 5318 页）

miR-9 downregulation[J]. Cell Death Dis, 2017, 8(3): e2646

[12] Zak M, Biskup M, Macek P, et al. Identifying predictive motor factors for falls in post-menopausal breast cancer survivors [J]. PLoS One, 2017, 12(3): e0173970

[13] Shastay A. Transdermal Iontophoretic FentaNYL PCA [J]. Home Healthc Now, 2017, 35(3): 174-175

[14] Li GZ, Fairweather M, Wang J, et al. Cutaneous Radiation-associated Breast Angiosarcoma: Radicality of Surgery Impacts Survival[J]. Ann Surg, 2017, 265(4): 814-820

[15] Kumar S, Palaniappan JM, Kishan A. Preemptive Caudal Ropivacaine: An Effective Analgesic during Degenerative Lumbar Spine Surgery[J]. Asian Spine J, 2017, 11(1): 113-119

[16] Sinaei F, Zendehdel K, Adili M, et al. Association Between Breast Reconstruction Surgery and Quality of Life in Iranian Breast Cancer Patients[J]. Acta Med Iran, 2017, 55(1): 35-41

[17] Wertli MM, Reich O, Signorell A, et al. Changes over time in prescription practices of pain medications in Switzerland between 2006 and 2013: an analysis of insurance claims [J]. BMC Health Serv Res, 2017, 17(1): 167

[18] Yamasaki Y, Yamasaki Y, Tsuboi J. A Case of Sentinel Lymph Node Biopsy for Male Breast Cancer [J]. Gan To Kagaku Ryoho, 2016, 43 (12): 2429-2431

[19] Kuwahara T, Tokuhisa Y, Suzuki N, et al. A Case of Ascending Colon Cancer with Extensive Abdominal Wall Abscess [J]. Gan To Kagaku Ryoho, 2016, 43(12): 2341-2343

[20] Nagashima S, Matsuo S, Takahashi M, et al. Effectiveness of Lenvatinib for Thyroid Cancer with Lung Metastases - Report of a Case[J]. Gan To Kagaku Ryoho, 2016, 43(12): 2121-2123

[21] Liu J, Dong W, Wang T, et al. Effects of etomidate and propofol on immune function in patients with lung adenocarcinoma [J]. Am J Transl Res, 2016, 8(12): 5748-5755

[22] Fujimori T, Kasagawa T, Ishii N, et al. Lung Metastasis of Breast Cancer Five Years after Mastectomy - A Case Report [J]. Gan To Kagaku Ryoho, 2016, 43(12): 2044-2046

[23] Liu WS, Mu L, Tang XC, et al. Impact of immediate breast reconstruction on the onset of adjuvant chemotherapy and on the postoperative complications [J]. Chinese Journal of Oncology, 2017, 39(1): 44-47

[24] Divella R, De Luca R, Abbate I, et al. Obesity and cancer: the role of adipose tissue and adipo-cytokines-induced chronic inflammation[J]. J Cancer, 2016,7(15): 2346-2359

[25] Liu WS, Mu L, Tang XC, et al. Impact of immediate breast reconstruction on the onset of adjuvant chemotherapy and on the postoperative complications [J]. Chinese Journal of Oncology, 2017, 39(1): 44-47

[26] Chang JH, Jeon W, Kim K, et al. Prognostic Significance of Inner Quadrant Involvement in Breast Cancer Treated with Neoadjuvant Chemotherapy[J]. J Breast Cancer, 2016, 19(4): 394-401

[27] Iyengar NM, Gucalp A, Dannenberg AJ, et al. Obesity and Cancer Mechanisms: Tumor Microenvironment and Inflammation [J]. J Clin Oncol, 2016, 34(35): 4270-4276

[28] Autenshlyus AI, Kunts TA, Karpukhina KV, et al. Cytokine pattern of the breast tumor supernatant [J]. Dokl Biol Sci, 2016, 470(1): 247-248

[29] Enomoto M, Yagishita K, Okuma K, et al. Hyperbaric oxygen therapy for a refractory skin ulcer after radical mastectomy and radiation therapy: a case report[J]. J Med Case Rep, 2017, 11(1): 5

[30] Chen HT, Sun D, Peng YC, et al. Novel augmentation by bufalin of protein kinase C-induced cyclooxygenase-2 and IL-8 production in human breast cancer cells[J]. Innate Immun, 2017, 23(1): 54-66

(上接第 5286 页)

[17] 张艺. 新型泡沫硬化剂聚桂醇在下肢静脉曲张治疗中的应用效果观察及相关分析[J]. 河北医学, 2014, 20(3): 380-383
Zhang Yi. Observation and correlation analysis of the application effect of the new type foam sclerosing agent in the treatment of varicose veins of lower extremity[J]. Hebei Medicine, 2014, 20(3): 380-383

[18] 胡丽, 黄惠真, 马刚, 等.聚桂醇泡沫硬化剂治疗浅表静脉畸形的疗效及安全性分析 [J]. 组织工程与重建外科杂志, 2014, 10(4): 196-198
Hu Li, Huang Hui-zhen, Ma Gang, et al. Efficacy and Safety of Sclerotherapy with Polidocanol Foam for Superficial Venous Malformation, 2014, 10(4): 196-198

[19] 王平. 改良大隐静脉高位结扎并剥脱术治疗原发性大隐静脉曲张的疗效及安全性评价[J]. 中国医师进修杂志, 2012, 35(2): 61-62
Wang Ping. Curative effect of modified ligation of large saphenous vein and stripping in the treatment of primary varicosis of great saphenous vein and evaluation of the safety [J]. Chinese Journal of Postgraduates of Medicine, 2012, 35(2): 61-62

[20] 焦亚彬, 耿园园, 杨奋有, 等. 聚桂醇泡沫硬化剂注射与腔内电凝治疗下肢静脉曲张的疗效对比 [J]. 中国全科医学, 2016, 19(5): 589-591
Jiao Ya-bin, Geng Yuan-yuan, Yang Fen-you, et al. Efficacy Comparison of Lauromacrogol Sclerotherapy and Intracavity Electrocoagulation in the Treatment of Varicose Vein of Lower Limb [J]. Chinese General Practice, 2016, 19(5): 589-591